Sherry Lynn Sanderson, DVM, PhD, Diplomate ACVIM & ACVN, University of Georgia

Body Condition Score Techniques for Dogs

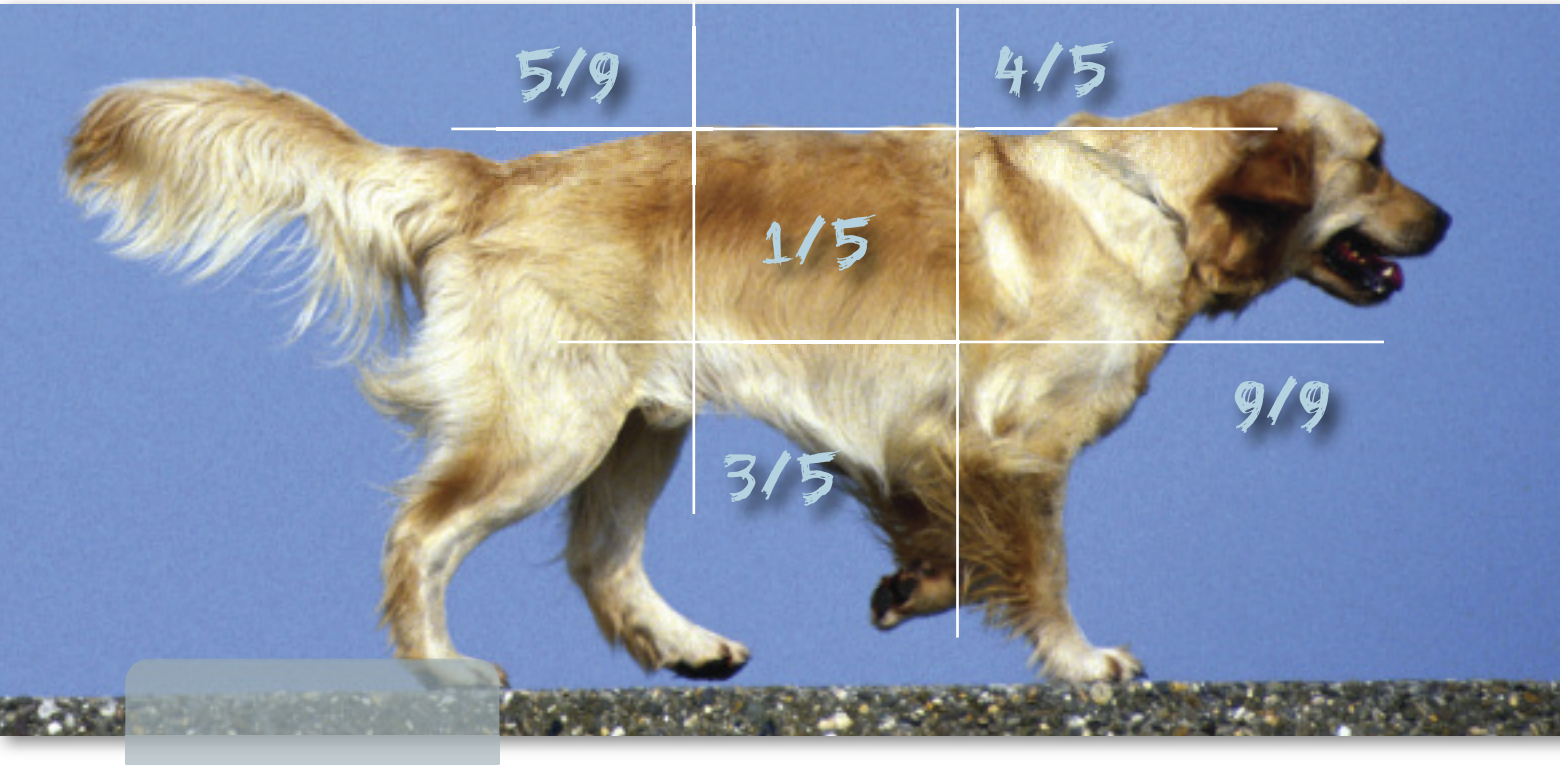

Body condition scores (BCS) is just as important to monitor in dogs as body weight. Assigning a BCS when recording body weight is useful to:

- Assess whether a dog's weight is appropriate
- Detect underlying disease (before outward clinical signs are present) and changes in nutritional status
- Detect small increases in body weight and BCS that can eventually lead to obesity.

BCS NUMERIC SCALES

Assessing BCS is a subjective and semiquantitative method for evaluating body fat that combines visual assessment (from the top and side) and palpation (waist, ribs and abdominal tuck, and dorsal spinous processes at tail base) to assess adipose tissue mass.

Two numeric scales are used for assigning BCS in dogs **(Table)**. Either scale can be used as long as the type of scale

CONTINUES

Table. Body Condition Scoring Scales

	Underweight	Ideal	Overweight
5-Point Scale	1 (very thin) 2 (underweight)	3	4 (overweight) 5 (obese)
9-Point Scale	1–3	4–5	6–9

is designated. For example, a dog with a BCS of 4 could be ideal or overweight, depending on which scale is used. However, if the BCS is recorded as 4/9 or 4/5, it is easy to determine the appropriateness of the dog's body weight.

ASSESSING BODY FAT

Despite the subjective nature of assigning a BCS, when assigned according to specific defined criteria, it is reliable for assessing body fat in dogs.[1] The correlation between BCS and percentage of body fat is highly significant (r = 0.90). Percentage body fat for ideal BCS (4–5/9 or 3/5) averages 20% and ranges from 15% to 25% of body weight. With the 9-point scale, each 1-point change from ideal represents an increase or decrease of 5%. With the 5-point scale, each point represents a 10% change.

BREED & AGE DIFFERENCES

There is a notable breed exception to average percentages. In a study by Jeusette and colleagues,[2] dual-energy x-ray absorptiometry was used to determine body fat percentage in a limited number of purebred dogs. Greyhounds appeared to have a higher muscle mass than other breeds. As a result, those with a BCS of 5/9 had a percentage body fat of 7.2%, which is significantly lower than the average percentage of 20%. Each 1-point change in BCS from ideal represented an increase or decrease of 1.5%. In contrast, huskies and Rottweilers with a BCS of 5/9 had a percentage body fat of 31% and 32%, respectively. In addition, increased age is associated with decreases in lean muscle mass and increases in fat mass.[3] Therefore, an older dog with a BCS of 5/9 may have a higher percentage body fat than a younger adult dog.

SCALE LIMITATIONS

Body fat percentge at the extreme upper or lower limits of the scales may not be precise—degree of emaciation or obesity may vary, yet only minimum and maximum scores can be assigned.. For example, 2 animals may be assigned the same BCS but have a percentage body fat that is quite different.

STEP BY STEP VISUAL ASSESSMENT

STEP 1

The dorsal and lateral appearance of a dog with an ideal BCS (3/5 or 5/9). The dog has a well-proportioned waist **(A)** and the abdominal tuck in front of the hind legs is well defined **(B)**.



EXPERT INSIGHT

Visual assessment of BCS is not very useful if the dog has long or thick hair.

EXPERT INSIGHT

A body weight noted in a medical record without a corresponding BCS provides very little information on how appropriate that body weight is for an individual animal.

STEP 2

The dorsal and lateral appearance of a dog with a BCS of 1/5 or 1/9 **(A and B)**. Note the bony prominences, evident from a distance, of the dorsal spinal processes, ribs, and hips. No discernible body fat is present, and there is an obvious loss of muscle mass. The dog in **C** also has the same BCS, but degree of emaciation is more severe. These figures illustrate that, when BCS is at the extreme end of the scale, the percentage body fat of 2 dogs with the same BCS can vary.



STEP 3

The dorsal and lateral appearance of a morbidly obese dog with a BCS of 5/5 or 9/9. Note lack of a visible waist and massive fat deposits present over the thorax, spine, and base of tail **(A)**, and the lack of an abdominal tuck and presence of a pendulous ventral bulge **(B)**. There are also massive fat deposits on the neck and limbs.

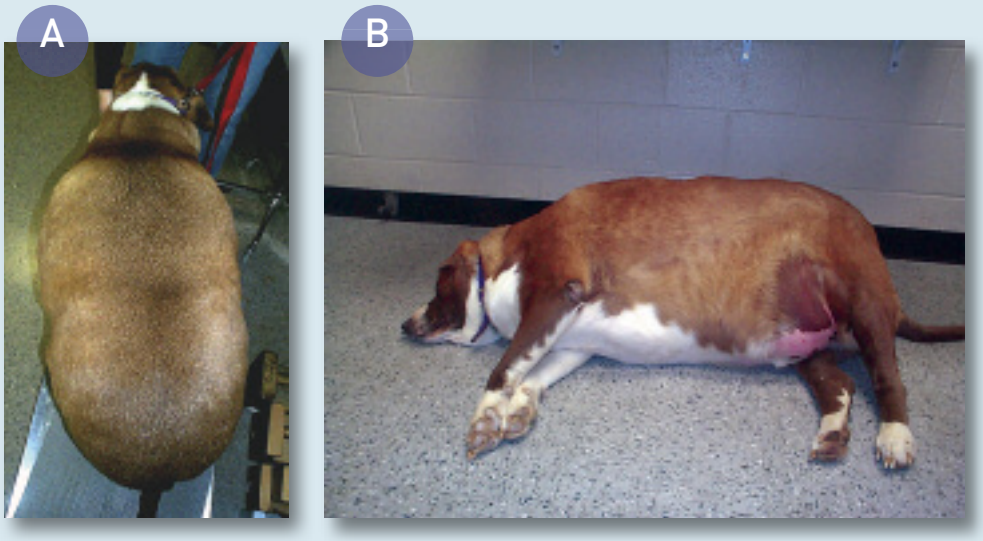

EXPERT INSIGHT

Determining when a dog has reached an ideal body weight is based more on BCS than actual weight; therefore, recording body weight and BCS simultaneously is important for weight-loss programs.

STEP 4

Appearance of an 8-week-old puppy with an ideal BCS (3/5 or 5/9) **(A)**. Note that, in puppies, appearance of the abdominal tuck in front of the hindlimbs is less pronounced than in adults with the same BCS. Figure **B** shows the appearance of a severely emaciated 8-week-old puppy with a BCS of 1/5 or 1/9. Note the very prominent abdominal tuck and easily visible bony prominence of the pelvic bones, ribs, and lumbar vertebrae. There is an obvious loss of muscle mass, especially on the hind leg, where the femur bone is easily visible.

EXPERT INSIGHT

A dog with a BCS of 4/5 or 7/9 correlates with a percentage body fat of 30%, which is similar to the critical percentage body fat for people who are overweight.

CONTINUES

STEP BY STEP PALPATION TECHNIQUE

STEP 1

Rib Palpation

Place both thumbs near the backbone and spread both hands across the rib cage. In dogs with an ideal BCS (3/5 or 4–5/9), individual ribs are palpable with no excess fat covering. In dogs with a BCS of 1/5 or 1/9, there is no discernible fat over the ribs. In dogs with a BCS of 4/5 or 7/9, the individual ribs are difficult to palpate due to the moderate level of fat covering them. In a dog with a BCS of 5/5 or 9/9, individual ribs are barely or not at all palpable.

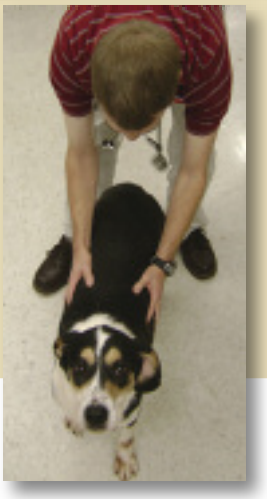

STEP 2

Waist Palpation

Place both thumbs near the backbone and fingers right behind the last rib. The width of the abdomen directly behind the last rib should be smaller than the width of the ribs, and should slightly increase near the pelvic region (hour-glass appearance).

EXPERT INSIGHT

For all palpation techniques, the dog should be in a standing position.

STEP 3

Tail-Base Area Palpation

Place the thumb on one hip bone and all other fingers except the index finger on the opposite hip bone. Use the index finger to palpate the dorsal spinous processes of the vertebrae in the region. Dogs with an ideal BCS of 3/5 or 4–5/9 should have a smooth contour in that area, but bones can be felt under a thin layer of fat. The hip bones and dorsal spinous processes become more prominent and may actually protrude in dogs that are underweight, and may not be palpable as the dog becomes obese. Obese dogs can also develop rolls of fat in the tail-base region that give the appearance of a dimple.

OVERWEIGHT VS OBESE

It is estimated that 24% to 44% of all dogs in the United States are overweight or obese, as are approximately 50% of dogs between the ages of 5 and 10 years. Dogs that are 10% to 20% above ideal body weight are considered overweight. Obesity, the excessive accumulation of adipose tissue in the body, occurs when dogs are > 20% above ideal body weight. It is the most common nutritional disorder detected in dogs.

See Aids & Resources, back page, for references and suggested reading.